

AFFIDAVIT

I, Wuwen Guo, translator in the City of Toronto, Province of Ontario, make oath and say:

1. I am fluent in both Chinese and English.
2. I have translated the annexed documents and carefully compared the translations from Chinese into English with regard to the following documents:

Medical Reports

3. The said translations are, to the best of my knowledge and ability, the complete and correct translations of said documents.

SWORN before me at the City of Toronto
In the Regional Municipality of Metropolitan
Toronto

This 18th day of Apr, 2025

A Notary Public in and for
Province of Ontario

Wuwen Guo

Wuwen Guo

JOSEPH JOURNAL

Tel: 416-409-2071

Add: 271



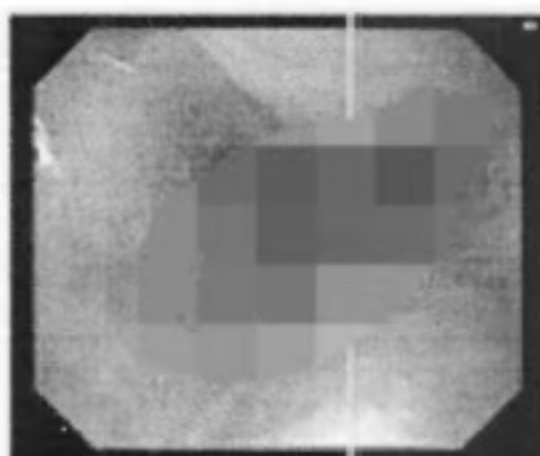
The First Affiliated Hospital of Zhengzhou University

Report of Gastroscopic Treatment

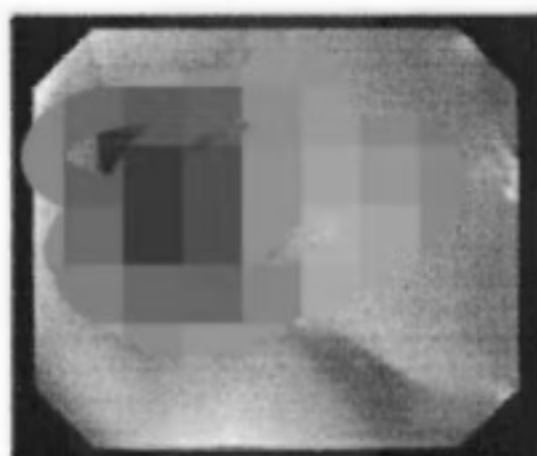
Name: [redacted] Gender: Male Age: [redacted] Application physician: [redacted]
Inpatient No.: [redacted] Tel: [redacted] Application Dept.: Digestive Endoscopy Center [redacted]
Address: [redacted]
Phone: [redacted]




1. Oesophagus



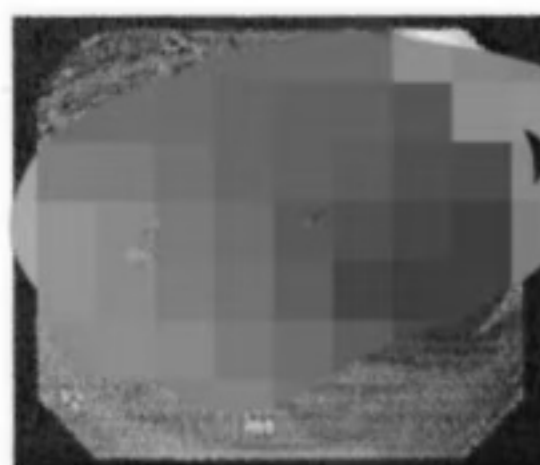
2. Oesophagus




3. Cardia



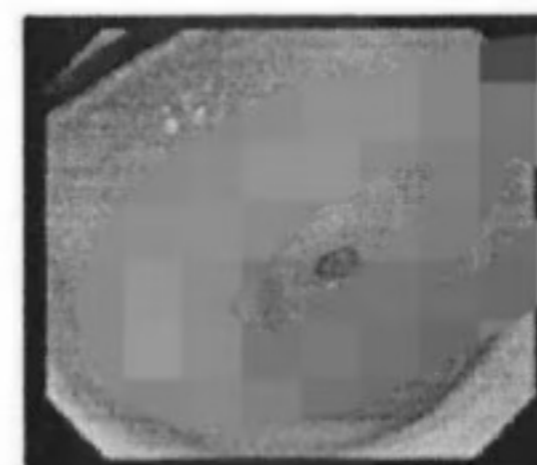
4. Gastric fundus



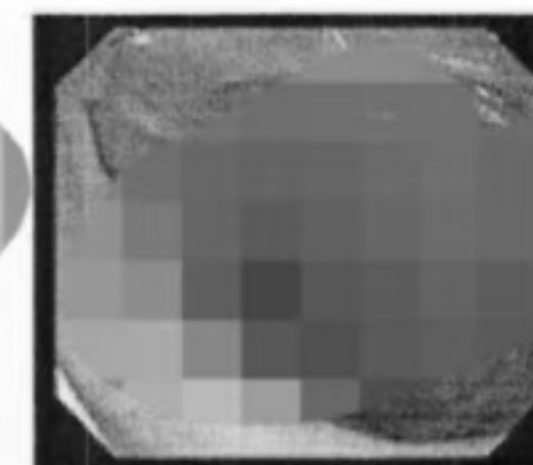
5. Gastric body



6. Gastric angle



7. Gastric antrum



8. Descending duodenum

Examination findings:

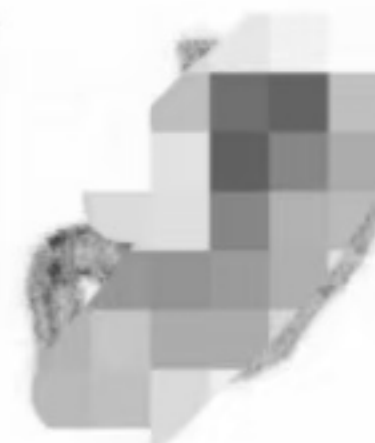The esophagus was smooth, with clear vascular texture and good peristalsis. The cardia could open and close freely, and the dentate line was clear. From the lower part of the gastric body to the gastric antrum, the mucosa was flat and thin, and the submucosal blood vessels could be seen through. There were no obvious abnormalities in the remaining gastric mucosa. The pylorus was round and opens well. No abnormalities were found in the gastric antrum cavity and the descending segment.

Diagnosis under Endoscopy:

- Normal esophagus
- Chronic atrophic gastritis

Pathological Diagnosis:

(Biopsy of gastric angle) It was severe chronic inflammation of the mucosa, with local lymphoid tissue hyperplasia.



Biopsy Site:
A: Gastric angle × 1

Report Physician: [redacted] Physician: [redacted] Examination Date: [redacted]


This report is only responsible for the results of this diagnosis!
This report will not be reissued if lost. Please keep it properly!
The First Affiliated Hospital of Zhengzhou University wishes you good health!

[redacted]
Barrister, Solicitor and Notary Public
[redacted]

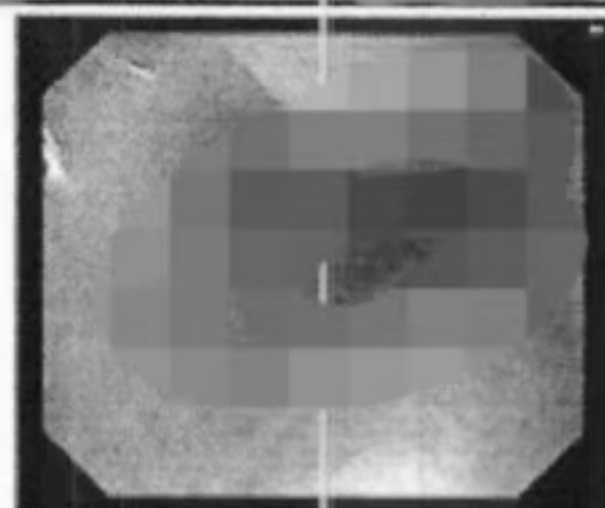


胃镜下治疗报告单

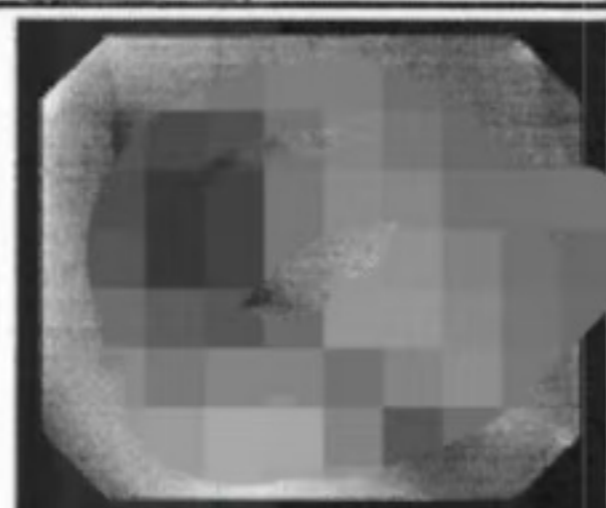
姓名: 性别: 年龄: 岁 申请医生:
住院号: 电话: 申请科室: 消化内镜中心(2)
地址: 检查号:




①食管




②食管




③贲门




④胃底



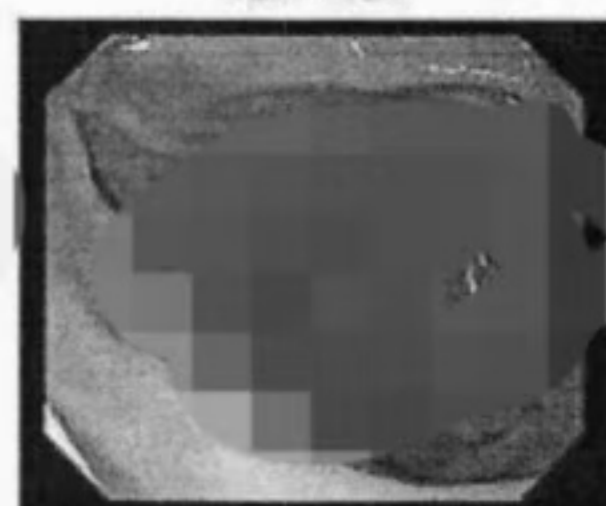
⑤胃体



⑥胃角



⑦胃窦



⑧降部

镜检所见: 食管光滑, 血管纹理清晰, 蠕动好, 贲门开闭自如, 齿状线清晰。于胃体下部至胃窦可见粘膜平薄, 粘膜下血管可透见, 其余胃粘膜无明显异常, 幽门圆, 开放好, 球腔及降段未见异常。

镜下诊断: 食管正常
慢性萎缩性胃炎

I certify that this is a true copy
of the original document.
Date: 5 day of Apr 2025

病理诊断: (胃角活检) 黏膜重度慢性炎, 局部淋巴组织增生

活检部位:

A: 胃角

报告医师:

医师签名:

检查日期:

本报告仅对本次诊断结果负责!

本报告丢失不补请妥善保管!

郑州大学第一附属医院祝您身体健康!